Case Reports in Oncology

Case Rep Oncol 2016;9:56–61

DOI: 10.1159/000433577
Published online: January 28, 2016

© 2016 The Author(s)
Published by S. Karger AG, Basel

1662–6575/16/0091–0056$39.50/0
www.karger.com/cro

This article is licensed under the Creative Commons Attribution-NonCommercial 4.0 International License (CC BY-NC) (http://www.karger.com/Services/OpenAccessLicense). Usage and distribution for commercial purposes requires written permission.

Pseudomyxoma Peritonei: Symptom Control and Objective Radiological Response after Treatment with Lanreotide Autogel

Gema Marín Zafra[a] Pedro Segura Luque[b]

Departments of [a]Medical Oncology and [b]Endocrinology, Hospital Universitario Virgen de la Arrixaca, Murcia, Spain

Key Words
Intestinal obstruction · Neuroendocrine tumour · Somatostatin analogue · Lanreotide Autogel®

Abstract
Peritoneal mucinous carcinomatosis is an aggressive subtype of pseudomyxoma peritonei, which often leads to inoperable bowel obstruction and, ultimately, death. Due to the poor prognosis, treatment is often symptomatic and aimed at alleviating the symptoms – pain, nausea, and vomiting – associated with gastrointestinal obstruction. Due to their antisecretory activity, somatostatin analogues are commonly prescribed in such cases. In the case presented here, a patient diagnosed with disseminated peritoneal mucinous carcinomatosis of appendiceal origin responded well to symptomatic treatment with lanreotide Autogel® at a dose of 120 mg/28 days. More importantly, radiological evidence of a reduction in peritoneal ascites, indicative of antiproliferative activity, was observed. These findings are important, particularly given the negative impact of this disease on both quality of life and survival. This case adds to the growing body of evidence supporting the antiproliferative and antisecretory activity of lanreotide Autogel.

© 2016 The Author(s)
Published by S. Karger AG, Basel

Introduction

Pseudomyxoma peritonei (PMP) is an extremely rare disease, with an annual incidence of approximately one case per million [1]. Although such tumours are typically slow-

KARGER

Gemma Marín Zafra
Department of Medical Oncology, Hospital Universitario Virgen de la Arrixaca
Ctra. Madrid-Cartagena, s/n, El Palmar
ES–30120 Murcia (Spain)
E-Mail gemarza@gmail.com

Downloaded from http://karger.com/cro/article-pdf/9/1/56/2522661/000433577.pdf by Consejeria de Sanidad user on 22 April 2026

growing, they vary highly in their invasive and metastatic capacity. Due to the heterogenous nature of PMP, a classification is difficult and controversial. Ronnett et al. [2] proposed dividing PMP into 3 categories: disseminated peritoneal adenomucinosis, peritoneal mucinous carcinomatosis (PMCA) – the most aggressive subtype – and an intermediate group with features of both subtypes. In contrast, other authors such as Misdraji [3] have suggested classifying the pathology into low- and high-grade disease.

The optimal treatment of PMP is unclear; however, the most common approach is surgical debulking with intraperitoneal chemotherapy during or immediately after surgery. In certain specialized centres, cytoreductive surgery with hyperthermic intraperitoneal chemotherapy is the treatment of choice [4].

PMCA typically originates from an appendiceal adenocarcinoma. Due to its invasive and metastatic characteristics, it has a poor prognosis. As the disease progresses, mucinous ascites accumulate in the peritoneum, eventually leading to gastrointestinal obstruction. Because this bowel obstruction is frequently inoperable, the main aim of treatment is to relieve the associated symptoms (primarily pain, nausea, and vomiting). Common symptomatic treatments include corticosteroids, antiemetics, and analgesics. Somatostatin analogues, such as lanreotide and octreotide, are also commonly used due to their antisecretory activity.

Here we describe a patient with appendiceal PMCA and peritoneal dissemination who responded well to symptomatic treatment with lanreotide, with radiological evidence demonstrating a notable reduction in peritoneal ascites.

Case Presentation

In July 2011, a 54-year-old female patient was referred to the Gynaecology Department for the evaluation of a suprapubic mass. Complementary tests performed during the diagnosis revealed the presence of several tumour markers [carbohydrate antigen 19–9 (CA 19–9): 45 U/ml; carcinoembryonic antigen (CEA): 2 ng/ml; carbohydrate antigen 125 (CA-125): 56 U/ml]. An abdominal ultrasound revealed a mass of 10 cm located on the anterior wall of the uterus, with scant free liquid in the peritoneal cavity.

The patient underwent an abdominal laparotomy in August 2011, revealing a 12-cm left adnexal mass with a stony consistency, identified as a signet ring cell carcinoma on intraoperative biopsy. A 4-cm tumour located on the right ovary was also observed, with similar characteristics to the adnexal mass.

A hysterectomy and double adenexectomy were performed, and the exploration of the abdominal cavity revealed a hardened appendix, with miliary seeding of the peritoneum and the diaphragmatic cupola. Given these findings, an appendicectomy and omentectomy were performed and multiple biopsies of the peritoneum were taken. R2 surgery was then performed, although the cytoreductive surgery was deemed incomplete due to the persistence of the macroscopic disease (>2.5 cm).

A pathological examination of the surgical specimen revealed a signet ring cell adenocarcinoma in the appendix, with metastases to the ovaries, fallopian tubes, omentum, and the left and right paracolic gutters. An immunohistochemical study showed a positive tinction for chromogranin and synaptophysin. The pathological diagnosis was appendiceal adenocarcinoma with neuroendocrine differentiation. The patient was not considered a candidate for hyperthermic intraperitoneal chemotherapy and was therefore referred to the Medical Oncology Department in September 2011 for further evaluation and treatment.

Downloaded from http://karger.com/cro/article-pdf/9/1/56/2522661/000433577.pdf by Conserjeria de Sanidad user on 22 April 2026

Results from an octreoscan were negative. First-line palliative chemotherapy was initiated according to the following scheme: capecitabine 2,000 mg/m^2/day for 14 days + oxaliplatin 130 mg/m^2 (6) for 4 cycles until January 2012, at which time second-line chemotherapy was initiated; day 1, 5-FU 400 mg/m^2 + LV 400 mg/m^2 + irinotecan 180 mg/m^2 + 5-FU 2,400 mg/m^2 in continuous perfusion for 46 h due to abdominal progression (tense ascites) and elevated serum tumour markers (CA 19–9: 104 U/ml). The patient received a total of 12 cycles of chemotherapy until June 2012 when treatment was halted due to unacceptable toxicity (diarrhoea and neutropaenia, both grade 3).

After the patient recovered from the chemotherapy-induced toxicity, bimonthly follow-ups in the outpatient clinic were initiated. Her general health status remained good, without any notable digestive symptoms and with an excellent functional status. However, in January 2013, the patient developed bowel obstruction secondary to tumour progression and was admitted to the hospital. An abdominal CT scan showed a peritoneal invasion, with a hypodense region surrounding both the liver and the spleen, and marked duodenal dilatation up to the ligament of Treitz.

Symptomatic treatment, including parenteral nutrition, corticosteroid therapy, antiemetics, and nasogastric intubation, was prescribed, with a good clinical response. The General Surgery Department (Peritoneal Carcinomatosis Unit) evaluated the patient for possible palliative surgery, but the case was considered unsuitable for surgery.

Symptom control during hospitalization was good and the nasogastric tube was removed due to a lack of vomiting episodes. The patient maintained adequate kidney, hematologic, and liver function, and she was discharged from the hospital to home care, which included continued parenteral nutrition, supportive care, and monthly follow-ups at the Medical Oncology Outpatient Department.

From March to November 2013, the patient presented a sufficient performance status [Eastern Cooperative Oncology Group (ECOG) grade 1] with no abdominal pain or bilious vomiting. Kidney, liver, and hematologic function were also adequate. She continued to receive home parenteral nutrition under supervision of the Nutrition Unit. No radiological changes were observed on any images taken during outpatient follow-up. The only change of note was an increase in serum levels of CA 19–9 (330 U/ml).

In January 2014, the number of bilious vomiting episodes increased to 3–4 per day. However, no worsening of other symptoms was observed, and kidney, liver, and hematologic functions remained adequate. Considering the neuroendocrine differentiation of the primary tumour in the context of the patient's increased vomiting frequency, we decided to initiate treatment with lanreotide Autogel (Somatuline Autogel®; Ipsen), a long-lasting extended-release gel formulation of lanreotide, at a dose of 120 mg every 28 days. A phase III trial published in 2012 suggested that this drug might be effective in the symptomatic treatment of inoperable bowel obstruction due to peritoneal carcinomatosis [5]. Our decision was further bolstered by a review published in that same year suggesting that somatostatin analogues may provide both direct and indirect antitumour effects in neuroendocrine tumours [6].

An abdominal CT scan performed after treatment with lanreotide Autogel showed a clear tumour response, with a notable decrease in ascites (fig. 1). In addition, vomiting frequency was reduced, and serum CA 19–9 decreased from 330 to 230 U/ml.

For several months, the patient continued treatment with lanreotide Autogel, home parenteral nutrition (without oral ingestion of food), and monthly check-ups. The vomiting frequency was just once per day. Her performance status (ECOG) was grade 2. Tolerance of the lanreotide was excellent without any notable adverse effects. However, in November 2014, the patient was hospitalized due to acute respiratory failure in the context of a lower airway

Downloaded from http://karger.com/cro/article-pdf/9/1/56/2522661/000433577.pdf by Conserjeria de Sanidad user on 22 April 2026

infection. A few days after admission, the patient died (on November 11, 2014) due to multi-organ failure (despite the use of antibiotics, oxygen therapy, and non-invasive ventilatory support).

Discussion

In the case report presented here, the use of lanreotide Autogel reduced disease-related symptoms, and, interestingly, also reduced the number of peritoneal ascites. These are important findings for patients with PMP given the highly negative impact of PMP-associated symptoms on quality of life and the poor long-term survival outcomes, especially in aggressive histological subtypes such as PCMA.

The benefits of short-acting somatostatin analogues (e.g., octreotide) for the symptomatic treatment in inoperable bowel obstruction are well documented [6–8]. Somatostatin analogues inhibit the release of various gastrointestinal hormones, thus reducing gastrointestinal secretions and slowing intestinal motility, and also increasing water and electrolyte absorption. Lanreotide microparticles, a synthetic somatostatin analogue, has also been proven efficacious for this indication [5]. Recently, the same formulation of lanreotide (lanreotide Autogel) that we used to treat the symptoms of bowel obstruction in our patient was reported to be efficacious in another case [9]. The authors of that case report highlighted an important advantage of long-acting lanreotide over octreotide: less frequent administration (three times/day for short-acting somatostatin analogues vs. once monthly administration for lanreotide Autogel).

In addition to the beneficial effects of somatostatin analogues on symptom control in secretory neuroendocrine tumours, several recent publications suggest that these drugs may also have direct and indirect antitumour effects. A systematic review published in 2012 evaluated publications that supported an antitumour role for the somatostatin analogues octreotide and lanreotide [6]. According to that review, the published data support an antitumour effect for these drugs. More recently, results were published from the CLARINET trial [10], a randomized, double-blind, placebo-controlled multinational study of lanreotide Autogel in patients with advanced, well- or moderately differentiated, grade 1 or 2 somatostatin receptor-positive neuroendocrine tumours. Patients randomized to receive Somatuline Autogel had a significantly longer progression-free survival, a finding that provides evidence for the antiproliferative effects of lanreotide.

Conclusions

In this case report, the use of lanreotide Autogel reduced disease-related symptoms and peritoneal ascites in a patient presenting with PMP. Randomized studies are needed to further investigate the antiproliferative effects of lanreotide observed in this patient, who had a neoplasm with neuroendocrine differentiation and a negative octreoscan.

Acknowledgement

The authors would like to thank Bradley Londres for his assistance in translating and improving the text.

Downloaded from http://karger.com/cro/article-pdf/9/1/56/2522661/000433577.pdf by Conserjeria de Sanidad user on 22 April 2026

Statement of Ethics

The paper submitted here is simply a descriptive report of treatment and outcomes. The patient's data have been completely anonymized and, therefore, no informed consent was considered necessary.

Disclosure Statement

The authors report no conflicts of interest.

References

1 Smeenk RM, Verwaal VJ, Zoetmulder FA: Pseudomyxoma peritonei. Cancer Treat Rev 2007;33:138–145.
2 Ronnett BM, Zahn CM, Kurman RJ, et al: Disseminated peritoneal adenomucinosis and peritoneal mucinous carcinomatosis. A clinicopathologic analysis of 109 cases with emphasis on distinguishing pathologic features, site of origin, prognosis, and relationship to 'pseudomyxoma peritonei'. Am J Surg Pathol 1995;19:1390–1408.
3 Misdraji J: Appendiceal mucinous neoplasms: controversial issues. Arch Pathol Lab Med 2010;134:864–870.
4 Elias DM, Ouellet JF: Intraperitoneal chemohyperthermia: rationale, technique, indications, and results. Surg Oncol Clin N Am 2001;10:915–933.
5 Mariani P, Blumberg J, Landau A, et al: Symptomatic treatment with lanreotide microparticles in inoperable bowel obstruction resulting from peritoneal carcinomatosis: a randomized, double-blind, placebo-controlled phase III study. J Clin Oncol 2012;30:4337–4343.
6 Sidéris L, Dubé P, Rinke A: Antitumor effects of somatostatin analogs in neuroendocrine tumors. Oncologist 2012;17:747–755.
7 Zelek L, Laval G, Asselain B: Somatostatin analogs for malignant bowel obstruction resulting from peritoneal carcinomatosis. J Clin Oncol 2013;31:2519–2520.
8 Mercadante S, Porzio G: Octreotide for malignant bowel obstruction: twenty years after. Crit Rev Oncol Hematol 2012;83:388–392.
9 Lybaert W: The use of lanreotide autogel® in the treatment of intestinal obstruction in a patient with adenocarcinoma. Case Rep Oncol 2014;7:43–46.
10 Caplin ME, Pavel M, Ćwikła JB, Phan AT, Raderer M, Sedláčková E, et al: Lanreotide in metastatic enteropancreatic neuroendocrine tumors. N Engl J Med 2014;371:224–233.

Downloaded from http://karger.com/cro/article-pdf/9/1/56/2522661/000433577.pdf by Conserjeria de Sanidad user on 22 April 2026

Case Rep Oncol 2016;9:56–61
DOI: 10.1159/000433577
© 2016 The Author(s). Published by S. Karger AG, Basel
www.karger.com/cro

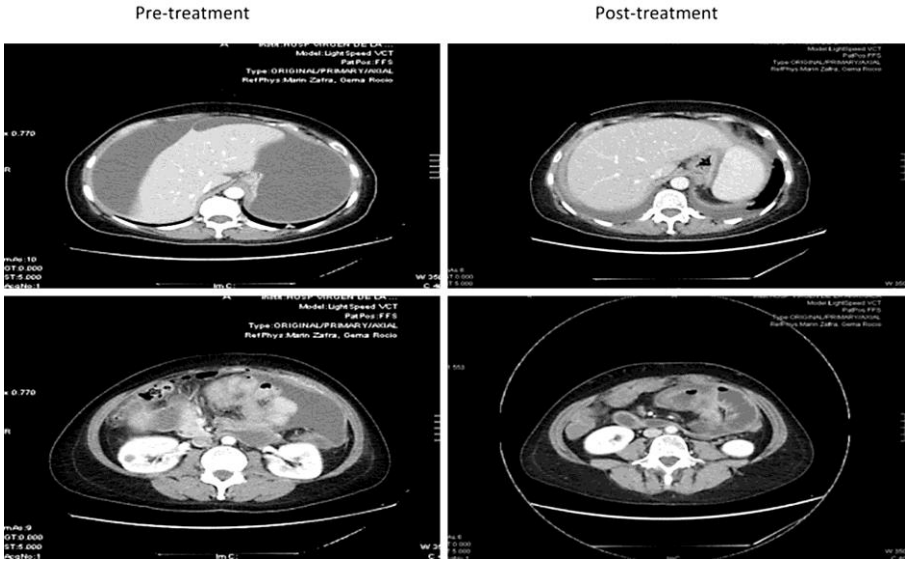

Fig. 1. Abdominal CT scans before and after treatment with lanreotide Autogel showing a decrease in ascites. The images on the left are before treatment and the images to the right are after treatment.

Downloaded from http://karger.com/cro/article-pdf/9/1/56/2522661/000433577.pdf by Conserjeria de Sanidad user on 22 April 2026