JOURNAL OF THE AMERICAN COLLEGE OF CARDIOLOGY VOL. 84, NO. 4, 2024
© 2024 THE AUTHORS. PUBLISHED BY ELSEVIER ON BEHALF OF THE AMERICAN COLLEGE OF CARDIOLOGY FOUNDATION. THIS IS AN OPEN ACCESS ARTICLE UNDER THE CC BY-NC-ND LICENSE (http://creativecommons.org/licenses/by-nc-nd/4.0/).

CASE REPORT

CLINICAL CASE

Septal Ablation to Treat Subaortic Dynamic Obstruction Following Transcatheter Aortic Valve Implantation

Lidia María Carrillo Mora, MD, José Javier Tercero Fajardo, MD, Diana Milena Cruz Sepúlveda, MD, Juan Ramón Gimeno Blanes, MD, PhD, Juan García De Lara, MD, PhD

ABSTRACT

Dynamic obstruction of the left ventricle is an unusual complication that can occur after aortic valve replacement. It is important to be aware of this pathology as it requires different management than normal complications and can rapidly lead to death. We present a case of successful resolution following transcatheter aortic valve implantation.
(J Am Coll Cardiol 2024;84:411–415) © 2024 The Authors. Published by Elsevier on behalf of the American College of Cardiology Foundation. This is an open access article under the CC BY-NC-ND license (http://creativecommons.org/licenses/by-nc-nd/4.0/).

HISTORY OF PRESENTATION

After evaluation by the Heart Team, an 87-year-old woman was considered for transcatheter aortic valve implantation (TAVI). Her vital signs were normal on admission (blood pressure: 123/81 mm Hg; pulse: 78 beats/min; temperature: 36.7 °C; oxygen saturation: 98%) and physical examination revealed a grade 4/6 systolic ejection murmur with no S2. A Navitor 25-mm aortic bioprosthesis was implanted. Hemodynamics and transthoracic echocardiography (TTE) did not reveal any complications. A few minutes later, the patient experienced severe hypotension (70/50 mm Hg) and rapidly progressive pulmonary edema, requiring respiratory support.

LEARNING OBJECTIVES

- To recognize DIG as a post-TAVI complication.
- To learn its proper management and therapeutic alternatives.

PAST MEDICAL HISTORY

She was diagnosed with severe aortic stenosis (AS) causing dyspnea on mild exertion. TTE showed a small left ventricle (LV) with a LV end-diastolic diameter of 33 mm. Ejection fraction was 71%, with LV hypertrophy and maximum septal thickness of 15 mm. She had an indexed ventricular mass of 122 g/m^2, moderate degenerative mitral regurgitation, and severe AS (maximum gradient 77 mm Hg, mean 43 mm Hg, and valve area 0.61 cm^2) (**Figure 1**). No dynamic intraventricular gradient (DIG) was detected.

DIFFERENTIAL DIAGNOSIS

Bioprostheses-related complications (mitral valve chordae rupture, tamponade, ventricular dysfunction, access site bleeding).

From the Cardiology Department, Hospital Universitario Virgen de la Arrixaca, Murcia, Spain.
The authors attest they are in compliance with human studies committees and animal welfare regulations of the authors' institutions and Food and Drug Administration guidelines, including patient consent where appropriate. For more information, visit the Author Center.

Manuscript received May 22, 2024; accepted May 22, 2024.

ISSN 0735-1097 https://doi.org/10.1016/j.jacc.2024.05.032

ABBREVIATIONS AND ACRONYMS

AS = aortic stenosis

DIG = dynamic intraventricular gradient

LV = left ventricle

SAM = systolic anterior mitral leaflet movement

TAVI = transcatheter aortic valve implantation

TTE = transthoracic echocardiography

INVESTIGATIONS

Intraprocedural transesophageal echocardiography showed a new-onset dynamic subaortic obstruction (peak gradient 60 mm Hg) and severe mitral regurgitation largely due to systolic anterior mitral leaflet movement (SAM) (**Figure 2**, Video 1A).

MANAGEMENT

Vasoactive support using phenylephrine and noradrenaline and esmolol intravenous infusion was started. The patient progressively improved and was admitted to the intensive care unit.

She showed moderate decongestion and was weaned from ventilatory support. Noradrenaline was gradually reduced, and she started taking oral bisoprolol and disopyramide. A temporary transjugular pacemaker was placed for 36 hours. However, significant subaortic obstruction persisted on TTE. Alcoholic septal ablation was performed successfully 5 days after the TAVI procedure (Video 2). Once euvolemic, she was discharged on oral medication despite residual mild subaortic obstruction and moderate mitral regurgitation (Video 1B).

DISCUSSION

The success of TAVI in treating patients with severe AS who have high surgical risk has been well established since 2002,[1] although it is not without risk.

Postimplantation cardiogenic shock is a feared complication that can have various causes, such as cardiac tamponade due to perforation, rupture of the annulus, coronary occlusion, or multifactorial ventricular dysfunction.[2] It is important to include ventricular suicide in the differential diagnosis. The term "LV suicide" was coined by Suh et al[3] due to the similarity of hemodynamic phenomena observed in the well-known "suicide" of the right ventricle after unobstruction of pulmonary stenosis.

LV suicide refers to the development of a high dynamic intracavitary gradient that leads to LV collapse, which mainly occurs in patients with asymmetric LV hypertrophy. This situation may be caused by a sudden decrease in afterload, resulting in a hyperdynamic ventricle and obstruction of blood flow. The obstruction can occur either at the level of the LV outflow tract with possible SAM, which is more frequent, or at the midventricular level.

Although clinical signs may resemble other common complications, such as marked hypotension or ventricular dysfunction, it is important to consider

FIGURE 1 Transthoracic Echocardiography Before Transcatheter Aortic Valve Implantation

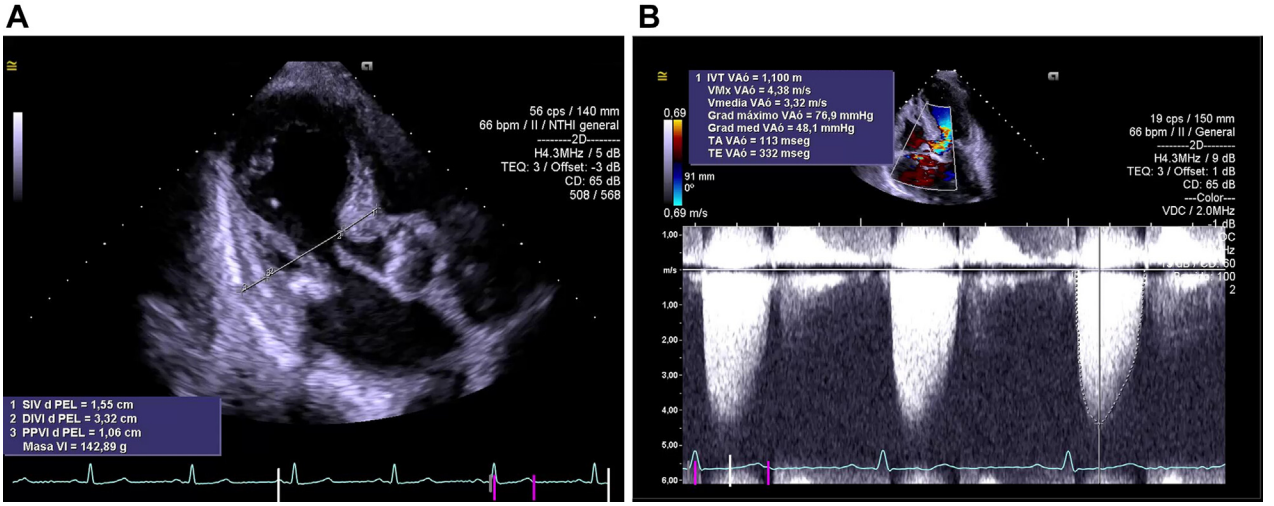

(A) Reduced left ventricular end-diastolic diameter and septal hypertrophy are shown. (B) Aortic stenosis with severe gradient.

FIGURE 2 **Intraprocedural Transesophageal Echocardiography**

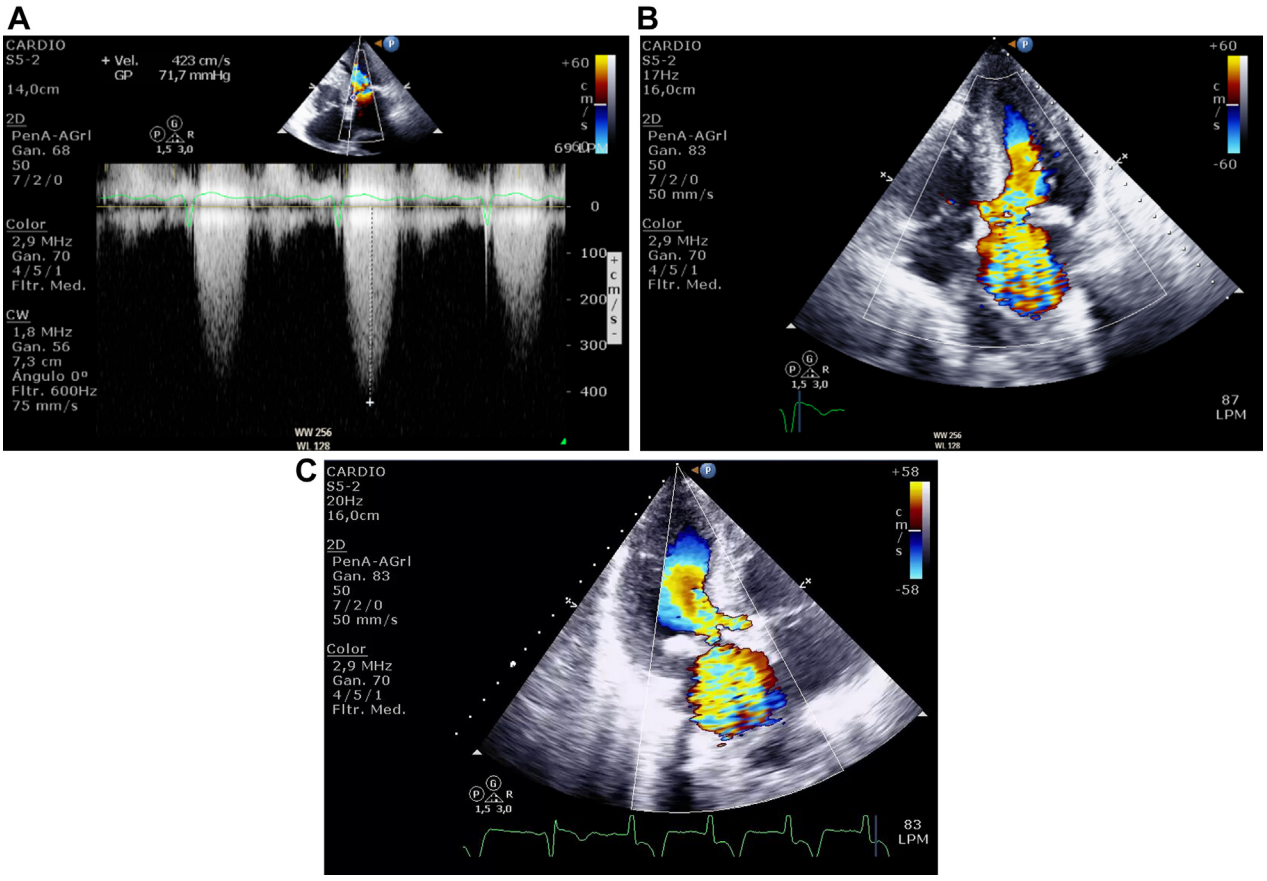

A significant subaortic dynamic gradient (A) and severe mitral regurgitation were detected in both the 4-chamber (B) and 3-chamber planes (C).

the possibility of this phenomenon to avoid incorrect treatment with vasoactive or inotropic drugs that may exacerbate the situation. Increasing ventricular filling pressures is the recommended treatment for this condition.[4] This is achieved with simple support measures such as intensive saline therapy, suspension of inotropic drugs, use of intravenous beta-blockers, use of phenylephrine, and even dual-chamber pacemakers to restore atrioventricular synchrony, as the importance of atrial contraction in the management of this phenomenon has recently been confirmed.[5]

With these initial measures, most cases can be stabilized, and the DIG may disappear after 3 months of follow-up. In addition, septal hypertrophy may return in 13%, according to other studies.[6]

For refractory cases, either in acute or postacute settings, invasive alternatives such as septal ablation can be useful. Our patient underwent a successful septal ablation procedure in which the basal area of the septum was ablated in order to correct obstruction to flow. Although there have been cases of successful ablation in mid-septal areas, the basal area is typically the most obstructive.[7] Another alternative would be to implant a TAVI in lower zones, although this solution is technically challenging and sometimes not feasible. However, for patients with a higher likelihood of developing this complication (such as those with preexisting subvalvular stenosis and septal hypertrophy), the CoreValve system could be an alternative. This approach was first used by Finkelstein et al,[8] intentionally placing the valve struts over part of the thickened septum and subaortic membrane, resulting in improved resolution of the SAM that these patients sometimes experience. Less often, implantation of

FIGURE 3 Post-Transcatheter Aortic Valve Implantation Transthoracic Echocardiography

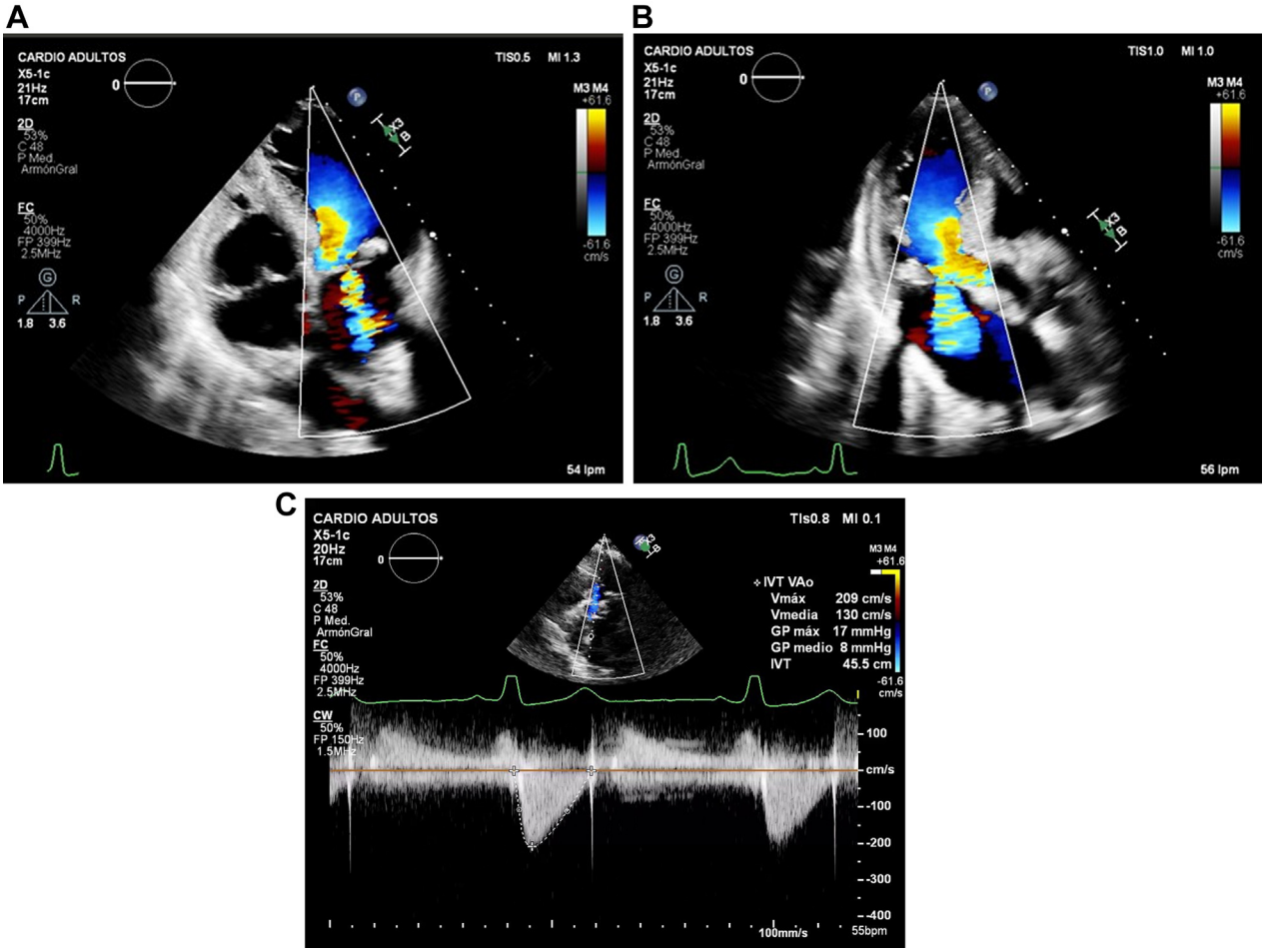

A significant decrease in mitral insufficiency is observed in both the 4-chamber (A) and 3-chamber planes (B), as well as the disappearance of the subaortic dynamic gradient (C).

bare-metal stents in the LV outflow tract has been reported as bail-out solution, despite the high rate of restenosis or stent fractures during follow-up.

On the other hand, invasive alternatives such as surgical myectomy or even Mitraclip implantation have been proposed for mitral regurgitation due to SAM.[9]

Finally, it is important to note that certain echocardiographic parameters can predict the development of DIG, which is defined as reaching a maximum velocity of 2.5 m/s or higher. López Ayerbe et al[6] identified several factors associated with DIG, including small LV end-diastolic diameter, high ejection fractions, high valvular gradients, high interventricular septal thickness to posterior wall thickness ratios, and small LV masses. However, a recent meta-analysis found that most patients with ventricular suicide were female and had a hypertrophic septum, small ventricle, and hyperdynamic contractility on echocardiographic evaluation before TAVI. This study also found that DIG was present in 50% of cases.[4] It is evident that our patient exhibited most of the characteristics identified by these publications, except for the assessment of DIG in our case.

FOLLOW-UP

A few days later, the patient's functional class improved with no signs of systemic congestion on examination and no DIG or SAM in the control TTE (Figure 3).

CONCLUSIONS

Although rare, ventricular suicide is a potential complication following TAVI, which can cause acute hemodynamic compromise and lead to death if not promptly addressed. Before valve implantation, echocardiography can provide essential information to anticipate this complication. Once established, simple support measures such as intensive saline therapy, avoiding inotropic drugs, and using intravenous beta-blockers, phenylephrine, and even dual-chamber to restore atrioventricular synchrony can restore hemodynamics. For refractory cases, alcoholic septal ablation can be a useful bail-out strategy.

FUNDING SUPPORT AND AUTHOR DISCLOSURES

The authors have reported that they have no relationships relevant to the contents of this paper to disclose.

ADDRESS FOR CORRESPONDENCE: Dr Lidia María Carrillo Mora, Cardiology Department, Hospital Universitario Virgen de la Arrixaca, Carretera Madrid-Cartagena, s/n, 30120 El Palmar, Murcia, Spain. E-mail: guigo41112@gmail.com. X handle: @juangdelara.

REFERENCES

1. Otto CM, Nishimura RA, Bonow RO, et al. 2020 ACC/AHA guideline for the management of patients with valvular heart disease: executive summary: a report of the American College of Cardiology/American Heart Association Joint Committee on Clinical Practice Guidelines. *J Am Coll Cardiol*. 2021;77(4):e25–e197.

2. Kim HN, Yang DH, Park BE. Acute decompensated heart failure after transcatheter aortic valve implantation: a case report. *Clin Case Rep*. 2023;11(7):e7597.

3. Suh WM, Witzke CF, Palacios IF. Suicide left ventricle following transcatheter aortic valve implantation. *Catheter Cardiovasc Interv*. 2010;76(4):616–620.

4. Barzallo D, Torrado J, Benites-Moya CJ, et al. Acute hemodynamic compromise after transcatheter aortic valve replacement due to dynamic left ventricle obstruction: a systematic review. *Am J Cardiol*. 2024;214:125–135.

5. Ibrahim H, Barker CM, Reardon MJ, et al. Suicide left ventricle due to conduction disturbance following transcatheter aortic valve replacement and reversal with restoration of sinus rhythm: is there life after death? *J Invasive Cardiol*. 2015;27(6):E107–E109.

6. López Ayerbe J, Evangelista Masip A, Armada Romero E, et al. Aparición de gradiente dinámico intraventricular después de la sustitución valvular aórtica en pacientes con estenosis aórtica severa [Predictive factors of abnormal dynamic intraventricular gradient after valve replacement in severe aortic stenosis]. Article in Spanish. *Rev Esp Cardiol*. 2002;55(2):127–134.

7. Gerckens U, Pizzulli L, Raisakis K. Alcohol septal ablation as a bail-out procedure for suicide left ventricle after transcatheter aortic valve implantation. *J Invasive Cardiol*. 2013;25(5):E114–E117.

8. Finkelstein A, Keren G, Banai S. Treatment of severe valvular aortic stenosis and subvalvular discrete subaortic stenosis and septal hypertrophy with percutaneous corevalve aortic valve implantation. *Catheter Cardiovasc Interv*. 2010;75(5):801–803.

9. Guerrero M, Wang DD, Himbert D, et al. Short-term results of alcohol septal ablation as a bail-out strategy to treat severe left ventricular outflow tract obstruction after transcatheter mitral valve replacement in patients with severe mitral annular calcification. *Catheter Cardiovasc Interv*. 2017;90(7):1220–1226.

KEY WORDS ablation, acute heart failure, aortic valve, complication, treatment, valve replacement

APPENDIX For supplemental videos, please see the online version of this paper.